

# Emergency Department Sonographic Measurement of Optic Nerve Sheath Diameter to Detect Findings of Increased Intracranial Pressure in Adult Head Injury Patients

**Vivek S. Tayal, MD**  
**Matthew Neulander, MD**  
**H. James Norton, PhD**  
**Troy Foster, MD**  
**Timothy Saunders, MD**  
**Michael Blaivas, MD**

From the Department of Emergency Medicine (Tayal, Neulander, Foster), and the Department of Biostatistics (Norton), Carolinas Medical Center, Charlotte, NC; the Charlotte Eye, Ear, Nose, and Throat Associates, Charlotte, NC (Saunders); and the Department of Emergency Medicine, Medical College of Georgia, Augusta, GA (Blaivas).

Dr. Neulander is currently affiliated with Northeast Medical Center, Concord, NC.  
Dr. Foster is currently affiliated with Lutheran General Hospital, Chicago, IL.

**Study objective:** Our objective is to determine whether a bedside ultrasonographic measurement of optic nerve sheath diameter can accurately predict the computed tomographic (CT) findings of elevated intracranial pressure in adult head injury patients in the emergency department (ED).

**Methods:** We conducted a prospective, blinded observational study on adult ED patients with suspected intracranial injury with possible elevated intracranial pressure. Exclusion criteria were age younger than 18 years or obvious ocular trauma. Using a 7.5-MHz ultrasonographic probe on the closed eyelids, a single optic nerve sheath diameter was measured 3 mm behind the globe in each eye. A mean binocular optic nerve sheath diameter greater than 5.00 mm was considered abnormal. Cranial CT findings of shift, edema, or effacement suggestive of elevated intracranial pressure were used to evaluate optic nerve sheath diameter accuracy.

**Results:** Fifty-nine patients were enrolled in the study. Average age was 38 years, and median Glasgow Coma Scale score was 15 (interquartile 6 to 15). Eight patients with an optic nerve sheath diameter of 5.00 mm or more had CT findings that correlated with elevated intracranial pressure. The sensitivity for the ultrasonography in detecting elevated intracranial pressure was 100% (95% confidence interval [CI] 68% to 100%) and specificity was 63% (95% CI 50% to 76%). The sensitivity of ultrasonography for detection of any traumatic intracranial injury found by CT was 84% (95% CI 60% to 97%) and specificity was 73% (95% CI 59% to 86%).

**Conclusion:** Bedside ED optic nerve sheath diameter ultrasonography has potential as a sensitive screening test for elevated intracranial pressure in adult head injury. [Ann Emerg Med. 2007;49:508-514.]

0196-0644/\$-see front matter

Copyright © 2007 by the American College of Emergency Physicians.

doi:10.1016/j.annemergmed.2006.06.040

## INTRODUCTION

Elevated intracranial pressure is a challenging and potentially fatal complication of acute head trauma in patients who present to the emergency department (ED).<sup>1,2</sup> This group of patients may require rapid intervention to prevent a poor outcome. Clinicians need an accurate tool to distinguish those with elevated intracranial pressure from the vast majority of patients with head injury who have no elevated intracranial pressure. The physical examination is limited in its ability to accurately detect elevated intracranial pressure caused by injury, sedation,

or paralysis as part of their out-of-hospital care.<sup>2</sup> Although computed tomography (CT) scanners are the most common diagnostic tests for these patients in US hospitals, there are situations in which a rapid bedside means of evaluating intracranial pressure would be advantageous. These situations include unstable multiorgan-system trauma patients, remote settings with prolonged transport time, or mass casualty occurrences.

The optic nerve sheath diameter has been suggested as a possible indicator of elevated intracranial pressure.<sup>3-7</sup> Our

### Editor's Capsule Summary

#### *What is already known on this topic*

Bedside indicators of intracranial pressure, such as the funduscopic examination, are neither sensitive nor specific.

#### *What question this study addressed*

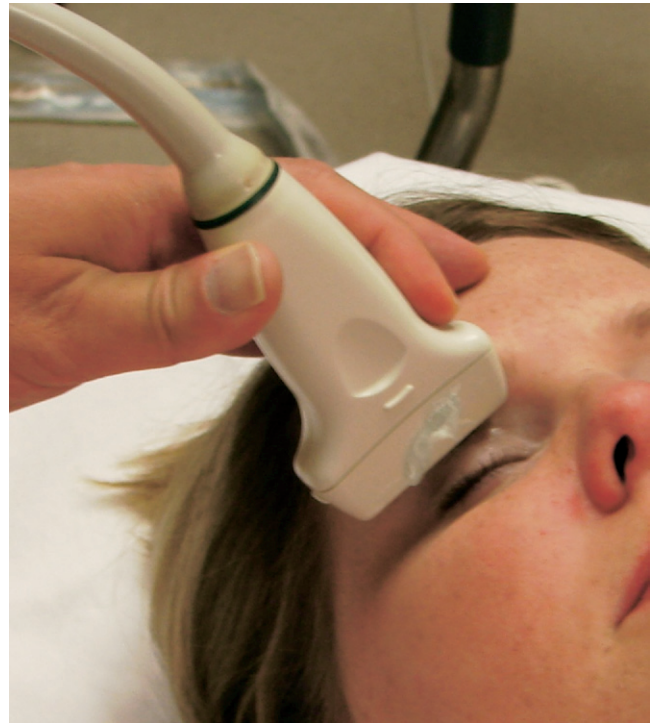In adults with head trauma, what is the sensitivity and specificity of bedside sonographic measurement of optic nerve sheath diameter for assessment of intracranial pressure?

#### *What this study adds to our knowledge*

In an emergency department population of 59 adults with head trauma, an optic nerve sheath diameter less than 5 mm excluded elevated intracranial pressure, as determined by computed tomography, with 100% sensitivity. Specificity was too low to be clinically helpful. Of note, because only 8 patients had elevated intracranial pressure, the lower limit of the 95% confidence interval for sensitivity was 68%.

#### *How this study might change clinical practice*

If these findings are independently replicated in cohorts with a higher prevalence of increased intracranial pressure, ocular sonography may allow physicians to rule out intracranial pressure elevation rapidly and noninvasively at the bedside in adults with head trauma.



**Figure 1.** Technique for ocular ultrasonography over closed eyelid.

objective was to determine whether dilation of the optic nerve sheath, as measured in the ED with a bedside ultrasonographic measurement, could accurately predict the findings of elevated intracranial pressure as seen in cranial CT in adult patients with acute head trauma.

## MATERIALS AND METHODS

### Study Design

We conducted a prospective, blinded, observational study on adult ED patients suspected of having elevated intracranial pressure as a result of acute head trauma. Patients or their representatives were provided informed consent before their inclusion in the study. This study was approved by the institutional review board of Carolinas Medical Center, Charlotte, NC.

### Setting

This research was conducted at a large, urban, regional, teaching ED and Level I trauma center with an annual census of 105,000 and annual major trauma volume of 2,000.

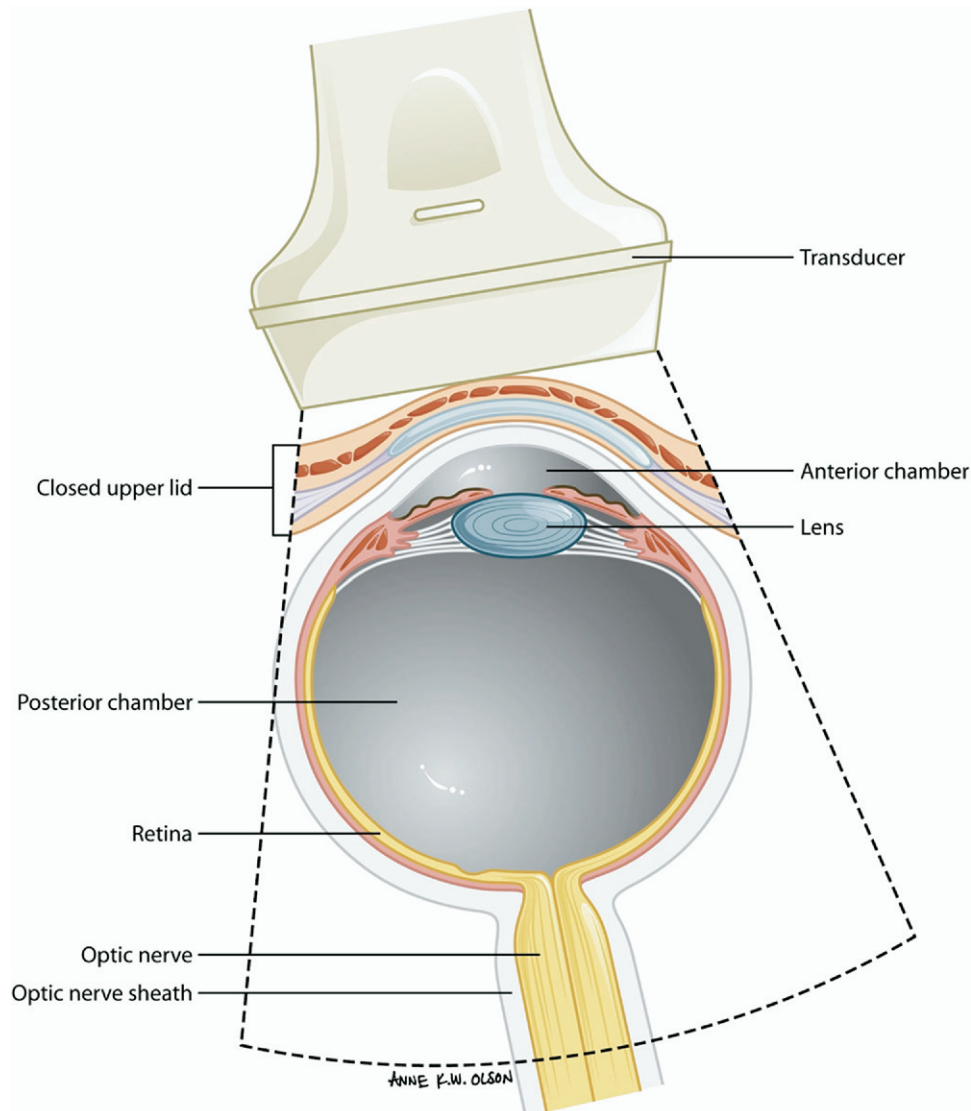
### Selection of Participants

All adult patients presenting to the ED with suspected acute head injury were eligible for the study. Exclusion criteria

included age younger than 18 years, patients with obvious bilateral ocular trauma, or enrollment delaying or interfering with formal diagnostics or interventions. Patients suspected of having acute intracranial injury who were scheduled to undergo head CT were enrolled in the study when a participating ED physician was available. The treating physician was asked for his assessment of the patient's intracranial pressure according to physical examination alone.

### Methods of Measurement

All enrolling study physicians were emergency physicians. A study physician scanned both eyes, using a 7.5-MHz linear probe on the closed eyelids of all study patients. If one eye was injured or was known to be artificial, only a unioocular optic nerve sheath diameter measurement was made over the unaffected eye. Shimadzu (Kyoto, Japan) SDU-400 and SDU 450 gray-scale ultrasonographic machines were used for ultrasonographic measurements. Ultrasonography was performed by using the following protocol described in the literature.<sup>1</sup> All patients were examined in the supine position. The linear probe was placed lightly over the closed upper eyelid(s) of the patient (Figure 1). The structures of the eye were visualized to align the optic nerve directly opposite the probe, but with the optic nerve sheath diameter width perpendicular to the vertical axis of the scanning plane (Figure 2). A single optic nerve sheath diameter was measured 3.00 mm behind the globe (Figure 3) in each eye, and then the optic nerve sheath diameter measurements from



**Figure 2.** Diagram of sonographic evaluation through closed eyelid of eye and optic nerve sheath diameter.

each eye were averaged to create a binocular optic nerve sheath diameter measurement. A binocular optic nerve sheath diameter or unocular measurement in those with one eye measurement (see above) greater than 5.00 mm was considered abnormal (Figure 4).

A CT scan of the head was performed on all patients, and the results were evaluated by an on-site radiologist blinded to the optic nerve sheath diameter ultrasonographic results. The patient's CT scan result was considered to be positive for ICP if the radiologist's reading described findings suggestive of elevated intracranial pressure previously suggested in the literature, namely, significant edema, midline shift, mass effect, effacement of sulci, collapse of ventricles, or compression of cisterns.<sup>2</sup>

#### Primary Data Analysis

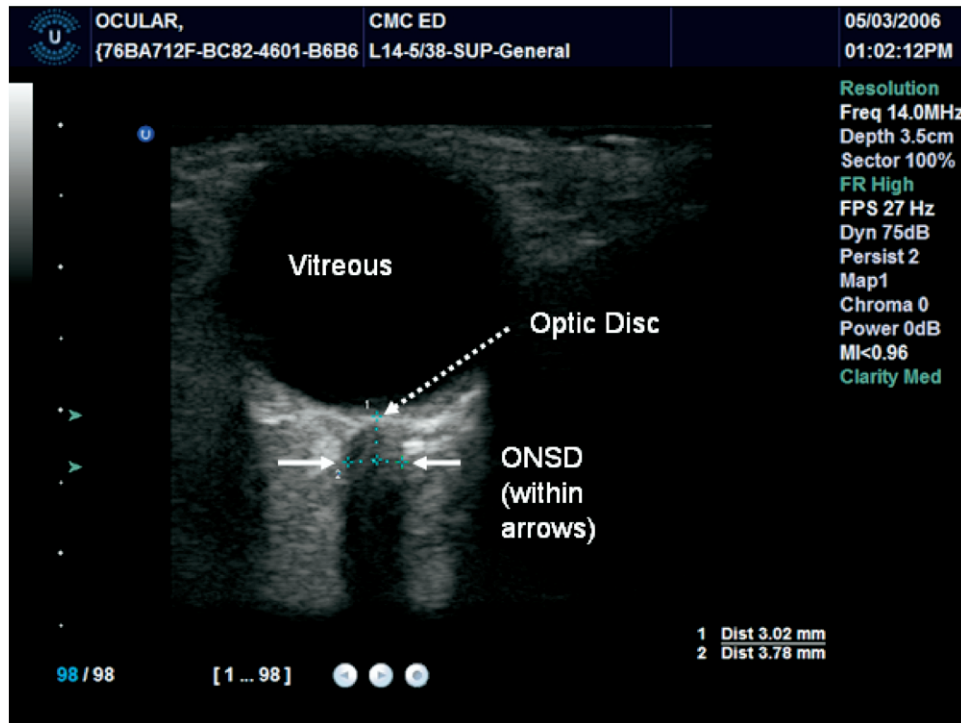
Ultrasonographic measurements, patient demographics, and cranial CT results were entered into a relational database

(Microsoft Access; Microsoft Corp., Redmond, WA).

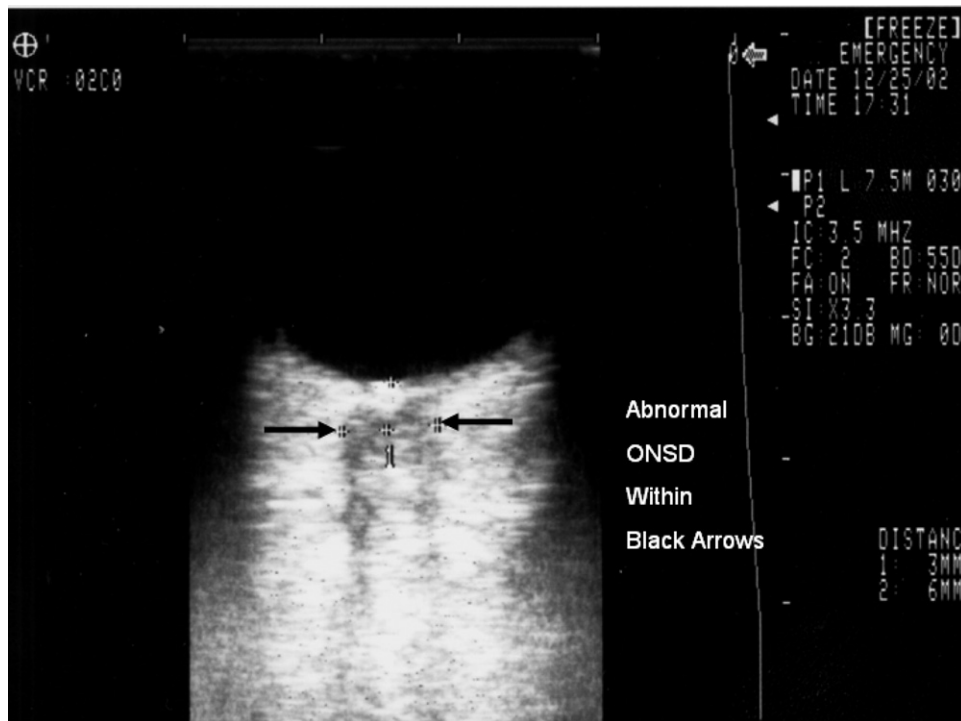Descriptive statistics were calculated via SAS (version 8.2; SAS Institute, Inc., Cary, NC). Sensitivity and specificity of mean binocular optic nerve sheath diameter (using 5.00 mm as the cutoff point) for detection or exclusion of elevated intracranial pressure were calculated using the radiologist's reading of the CT as the criterion standard for presence of absence of elevated intracranial pressure. Corresponding 95% confidence intervals (CIs) were calculated.

#### RESULTS

Fifty-nine patients were enrolled in the study, with an average age of  $38 \pm 17$  (SD) years, with 72% male sex. Most of our patients were motor vehicle crash patients (76%), but other mechanisms of injury were represented, including falls (12%), blunt assault (9%), and penetrating assault (3%). The population had a median Glasgow Coma Scale (GCS) score of 15



**Figure 3.** Ultrasonographic image of normal optic nerve sheath diameter measurement. Distance 1 is the distance (3 mm) behind the optic disc where the optic nerve sheath diameter (ONSD) is measured in its width. Distance 2 (between the white arrows) is the ONSD (3.78 mm).

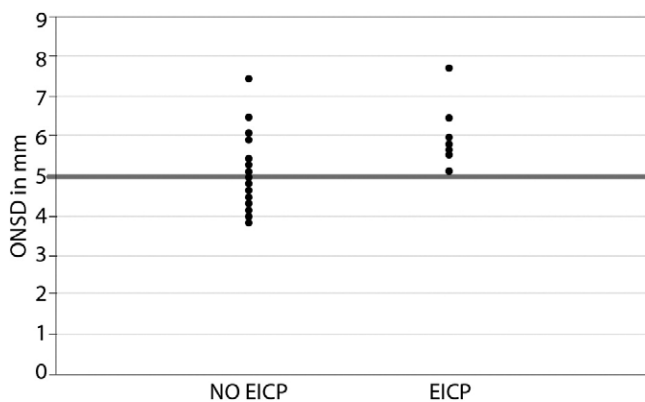


**Figure 4.** Ultrasonographic image of abnormal optic nerve sheath diameter measurement. Distance 1 is the distance (3 mm) behind the optic disc where the optic nerve sheath diameter (ONSD) is measured in its width. Distance 2 (between the black arrows) is the ONSD (6 mm).

**Table.** Characteristics of the 8 patients with increased optic nerve sheath diameter and elevated intracranial pressure.

Patient	Mean Binocular ONSD, mm	ONSD Right Eye, mm	ONSD Left Eye, mm	GCS	CT findings of ICP				
					Shift	Edema	Effacement	Collapse of Third Ventricle	Compression of Mesencephalic Cisterns
1	6.50	7.00	6.00	6	X			X	X
2	6.00	6.00	6.00	3		X			
3	5.85		5.85	3	X	X	X		
4	5.70	5.82	5.59	14	X				
5	7.75	8.04	7.46	3	X	X	X		X
6	5.77	5.00	6.54	6	X	X			X
7	5.16	5.52	4.80	4	X	X	X		X
8	5.56	5.62	5.51	15		X			

ONSD, Optic nerve sheath diameter.



**Figure 5.** Mean binocular optic nerve sheath diameter versus presence of optic nerve sheath diameter. Blue dots represent data values for each patient, stratified by presence or absence of elevated intracranial pressure. EICP, Elevated intracranial pressure.

(IQR 6 to 15); 16 were patients intubated at ultrasonography, either by out-of-hospital personnel or in the trauma bay. Fifty-four patients had binocular measurements, and 5 patients had unioocular measurement only.

Eight patients with a mean binocular optic nerve sheath diameter of 5.00 mm or more had CT findings of elevated intracranial pressure. The mean optic nerve sheath diameter for the 8 patients with CT evidence of elevated intracranial pressure was 6.27 mm (95% CI 5.54 to 6.96 mm). The mean binocular optic nerve sheath diameter of the other 51 patients was 4.94 mm (95% CI 4.74 to 5.15 mm), with a difference between groups of 1.33 mm (95% CI 0.766 to 1.866 mm). The Table describes the optic nerve, GCS, and CT findings on the 8 patients with increased optic nerve sheath diameter and elevated intracranial pressure. Figure 5 diagrams the mean binocular optic nerve sheath diameter of the population, stratified by the presence of elevated intracranial pressure.

Treating physicians' clinical assessment for elevated intracranial pressure were obtained in 52 of 59 (88%) patients

and revealed a sensitivity of 25% (95% CI 7% to 60%) and a specificity of 75% (95% CI 60% to 85%) compared to cranial CT findings of elevated intracranial pressure.

The sensitivity for the mean binocular optic nerve sheath diameter ultrasonography in detecting elevated intracranial pressure was 100% (95% CI 68% to 100%), and the specificity was 63% (95% CI 50% to 76%). With a prevalence of elevated intracranial pressure of 13.6%, the positive predictive value was 30% (95% CI 12% to 47%), and the negative predictive value was 100% (95% CI 91% to 100%). The sensitivity of mean binocular optic nerve sheath diameter ultrasonography for any traumatic intracranial injury found by CT was 84% (95% CI 60% to 97%), and the specificity was 73% (95% CI 59% to 86%).

**LIMITATIONS**

This study had several limitations, most notably its small size, observational methods, and convenience sampling. In addition, 5 patients had only 1 eye measured, which may have affected the derived statistical accuracy.

The study center physicians were experienced with ultrasonography in the emergency setting, and those centers with less experience may find varying results.

The criterion standard used as follow-up and comparison with the optic nerve sheath diameter ultrasonography is not a direct measurement of ICP. Direct measurement of ICP is an unrealistic and aggressive requirement, especially for patients with minor head injury. As a surrogate, head CT in the setting of acute trauma has shown limited accuracy in the identification and exclusion of elevated intracranial pressure in several published studies.<sup>8,9</sup>

**DISCUSSION**

The evaluation of the head injury patient with elevated intracranial pressure in the setting of multiple trauma presents significant challenges. Most head injury patients have concomitant injuries that require detection and treatment.<sup>1</sup> Findings of severe head injury can be various and nonspecific. The findings of severe head injury with elevated intracranial

pressure often alter the treatment for trauma patients.<sup>10</sup> Such decisions include transfer to the operating room versus the CT suite, treatment with medications such as mannitol, and placement of intracranial pressure monitors or drainage catheters.<sup>2,11,12</sup>

There is no means of detecting elevated intracranial pressure in a rapid, noninvasive, bedside manner, with the exception of the physical examination. Unfortunately, the ability to detect elevated intracranial pressure by examination alone is difficult and inexact. Additionally, the limitations increase significantly if the patient is unconscious, sedated, or paralyzed and intubated. Altered respiratory patterns from increasing ICP are extremely variable. Papilledema and pupillary changes are late findings that can take hours to appear. Performing a lumbar puncture during the trauma resuscitation is not feasible and, at worst, could be dangerous for the patient. Although cranial CT is available to most physicians in the US emergency practice environment, cranial CT requires both time and transport away from the monitoring or resuscitative resources of the emergency or critical care suite.<sup>13</sup>

This study suggests that a bedside sonographic test performed by the treating physician can rule out elevated ICP. Although this was a small patient sample and at 1 institution, other studies have reported similar findings in other mixed-patient populations with other inclusion criteria.<sup>7</sup>

We suggest that optic nerve sheath diameter offers further tools for physicians who treat head injury beyond physical examination and GCS. The fact that optic nerve sheath diameter had a reasonable sensitivity for any traumatic head injury suggests the need for further research in other settings and age ranges for the evaluation, stratification, and possible acute treatment of head injury.

Those with bedside sonographic experience may be able to learn this technique relatively quickly. In our estimation, the learning curve for the experienced sonologist may include as few as 10 subjects with 3 abnormal scan results, whereas for novice sonologists, the number of scans needed in this application may be closer to 25. In addition, correct equipment with high-frequency transducers with good lateral resolution will allow accurate scanning of the optic nerve sheath diameter.

The practical extension of the study results, if validated in larger studies, is that with small portable sonographic machines, the evaluation of the head injured patient for elevated intracranial pressure could possibly occur with triage and management implications. In the setting of disaster or simultaneous multiple trauma patients, a rapid bedside test would be helpful. The ability to rule out elevated intracranial pressure among several unconscious victims would help select the person most in need of rapid transport to an appropriate facility. Portable ultrasonography could be used during long transport times to better monitor acutely ill patients and institute treatment protocols for possible elevated intracranial pressure. Monitoring of hospitalized patients with elevated

intracranial pressure would be assisted by such a test, as the movement of such patients requires tremendous expenditure of nursing and hospital resources.

Bedside ED optic nerve sheath diameter ultrasonography has potential as a sensitive screening test for elevated intracranial pressure in adult head injury. Further work using optic nerve sheath diameter in these patients and other elevated intracranial pressure patients is warranted.

---

*Supervising editor:* E. John Gallagher, MD

*Author contributions:* VST and MB conceived the study and designed the trial. VST supervised the conduct of the trial and data collection. VST, MN, TF, and TS undertook recruitment of participating centers and patients and managed the data, including quality control. HJN provided statistical advice on study design and analyzed the data. VST drafted the article, and all authors contributed substantially to its revision. VST takes responsibility for the paper as a whole.

*Funding and support:* The authors report this study did not receive any outside funding or support.

*Publication dates:* Received for publication May 3, 2006. Revisions received May 30, 2006; June 6, 2006; and June 9, 2006. Accepted for publication June 13, 2006. Available online September 25, 2006.

Presented at the annual meeting of the Society of Academic Emergency Medicine, May 2005, New York, NY.

Reprints not available from the authors.

*Address for correspondence:* Vivek S. Tayal, MD, Box 32861, Charlotte, NC 28232; 704-355-3181, fax 704-355-7047; E-mail vtayal@carolinas.org.

---

## REFERENCES

1. American College of Surgeons. *Head Trauma*. Chicago, IL: American College of Surgeons; 1997:181-206.
2. Brain Injury Foundation, American Association of Neurological Surgeons, Joint Section on Neurotrauma and Critical Care. Initial management. *J Neurotrauma*. 2000;17:463-469.
3. Galetta S, Byrne S, Smith J. Echographic correlation of optic nerve sheath size and cerebrospinal fluid pressure. *J Clin Neuroophthalmol*. 1989;9:79-82.
4. Hansen H, Helmke K. Validation of the optic nerve sheath response to changing cerebrospinal fluid pressure: ultrasound findings during intrathecal infusion tests. *J Neurosurg*. 1997;87:34-40.
5. Helmke K, Hansen H. Fundamentals of transorbital sonographic evaluation of optic nerve sheath expansion under intracranial hypertension, I: experimental study. *Pediatr Radiol*. 1996;26:701-705.
6. Helmke K, Hansen H. Fundamentals of transorbital sonographic evaluation of optic nerve sheath expansion under intracranial hypertension, II: patient study. *Pediatr Radiol*. 1996;26:706-710.
7. Blaivas M, Theodoro DL, Sierzenski P. Elevated intracranial pressure detected by bedside emergency ultrasonography of the optic nerve sheath. *Acad Emerg Med*. 2003;10:376-381.
8. Miller M, Pasquale M, Kurek S, et al. Initial head computed tomographic scan characteristics have a linear relationship with

- initial intracranial pressure after trauma. *J Trauma*. 2004;56:967-973.
9. Malayeri AA, Bavarian S, Mehdizadeh M. Sonographic evaluation of optic nerve diameter in children with raised intracranial pressure. *J Ultrasound Med*. 2005;24:143-147.
  10. Brain Injury Foundation, American Association of Neurological Surgeons, Joint Section on Neurotrauma and Critical Care. Computer tomography scan features. *J Neurotrauma*. 2000;17:597-627.
  11. Biros M, Heegard W. Prehospital and resuscitative care of the head-injured patient. *Crit Opinion Crit Care*. 2001;7:444-449.
  12. Brain Injury Foundation, American Association of Neurological Surgeons, Joint Section on Neurotrauma and Critical Care. Recommendations for intracranial pressure monitoring technology. *J Neurotrauma*. 2000;17:497-506.
  13. Romagnulo L, Tayal VS, Tomaszewski CA, et al. Optic nerve sheath diameter does not change with patient position. *Am J Emerg Med*. 2005;23:686-688.