

# Prospective Evaluation of Thoracic Ultrasound in the Detection of Pneumothorax

Scott A. Dulchavsky, MD, PhD, Karl L. Schwarz, MD, Andrew W. Kirkpatrick, MD, Roger D. Billica, MD, David R. Williams, MD, Lawrence N. Diebel, MD, Mark R. Campbell, MD, Ashot E. Sargysan, MD, and Douglas R. Hamilton, MD, PhD

**Background:** Thoracic ultrasound may rapidly diagnose pneumothorax when radiographs are unobtainable; the accuracy is not known.

**Methods:** We prospectively evaluated thoracic ultrasound detection of pneumothorax in patients at high suspicion of pneumothorax. The presence of "lung sliding" or "comet tail" artifacts were determined in patients by ultrasound before radiologic verification of pneumo-

thorax by residents instructed in thoracic ultrasound. Results were compared with standard radiography.

**Results:** There were 382 patients enrolled; the cause of injury was blunt (281 of 382), gunshot wound (22 of 382), stab wound (61 of 382), and spontaneous (18 of 382). Pneumothorax was demonstrated on chest radiograph in 39 patients and confirmed by ultrasound in 37 of 39 patients (95% sensitivity); two pneumothoraces

could not be diagnosed because of subcutaneous air; the true-negative rate was 100%.

**Conclusion:** Thoracic ultrasound reliably diagnoses pneumothorax. Expansion of the focused abdominal sonography for trauma (FAST) examination to include the thorax should be investigated for terrestrial and space medical applications.

**Key Words:** Pneumothorax, Ultrasound, Space medicine.

*J Trauma.* 2001;50:201–205.

Pneumothorax is commonly associated with blunt or penetrating chest trauma or can spontaneously occur in susceptible patients. The diagnosis of pneumothorax is suggested by clinical signs and symptoms and is generally confirmed by chest radiography. Although the ability to obtain a chest radiograph is usually present without significant delay in the emergency room or hospital ward, occasionally, patient instability or difficulties in transport or radiographic availability require the diagnosis to be made clinically and definitive treatment accomplished before radiologic verification.

Pneumothorax can occur in patients in remote areas where radiographic evaluation is delayed or impossible such as in field military conflicts, rural medicine, or potentially during space exploration. Power, weight, and space requirements make radiography impractical in these applications; therefore, sound clinical diagnosis is paramount.<sup>1</sup> Unfortunately, environmental effects such as noise and possibly lim-

ited training of health care providers in these situations further complicate the diagnosis of pneumothorax.<sup>2</sup>

Definitive care of patients with pneumothorax in these settings is especially problematic. Placement of a chest tube in the field or in microgravity poses additional technical demands as well as having significant impact on the patient's ability to continue their duties or mission.<sup>3</sup> These considerations underscore the need for exploring the efficacy of alternative diagnostic methods to confirm the presence of a pneumothorax before definitive care.

Recent case reports have suggested that ultrasound may provide a rapid, noninvasive method to detect the presence of pneumothorax (Schwarz et al., unpublished data).<sup>4</sup> This study prospectively evaluates the sensitivity and specificity of thoracic ultrasound, performed by surgical residents trained in thoracic ultrasonography, against routine radiography in the diagnosis of pneumothorax in surgical patients.

## MATERIALS AND METHODS

The study protocol was approved by the University Human Investigation Committee and the National Aeronautics and Space Administration-Johnson Space Center Investigational Review Board. All stable patients with a clinical history and physical examination suggestive of pneumothorax presenting to the emergency room at Detroit Receiving Hospital, a Level I urban trauma center, were assessed for study inclusion. The patients were identified by the emergency medicine attending physicians or the trauma team, which consisted of surgical attending physicians with surgical and emergency medical residents. Patients were eligible with blunt or penetrating chest injury or with a history suggestive of spontaneous pneumothorax.

Submitted for publication October 17, 2000.

Accepted for publication November 16, 2000.

Copyright © 2001 by Lippincott Williams & Wilkins, Inc.

From the Department of Surgery (S.A.D., K.L.S., L.N.D.), Wayne State University School of Medicine, Detroit, Michigan, Vancouver General Hospital (A.W.K.), Vancouver, British Columbia, Canada, National Aeronautics and Space Administration (S.A.D., R.D.B., D.R.W.), Space and Life Science Directorate, Johnson Space Center, and Wyle Laboratories (M.R.C., A.E.S., D.R.H.), Houston, Texas.

Presented at the 60th Annual Meeting of the American Association for the Surgery of Trauma, October 11–15, 2000, San Antonio, Texas.

Address for reprints: Scott A. Dulchavsky, MD, PhD, Department of Surgery, Detroit Receiving Hospital, 4201 St. Antoine, Detroit, MI 48201.

## Inclusion Criteria

Inclusion criteria consisted of the following: ability to give informed consent, stable vital signs, age range 18 to 80 years, and no preexisting pulmonary conditions such as pulmonary surgery or lung disease.

## Exclusion Criteria

Exclusion criteria consisted of the inability to give informed consent; unstable vital signs; preexisting pulmonary disease; and chest wall injury, skin loss, or subcutaneous emphysema precluding adequate ultrasound evaluation.

## Ultrasound Training and Technique

All of the ultrasound examinations were performed by surgical residents or attending physicians familiar with ultrasound for abdominal trauma who had attended a formal ultrasound course for surgeons. The residents also were instructed in the principles of thoracic ultrasound with hands-on demonstration of the normal ultrasound findings in models with normal lung anatomy. Finally, the majority of the residents viewed a prerecorded ultrasound examination of a patient with a pneumothorax that clearly demonstrated the lack of pleural sliding seen in patients with lung collapse.

Informed consent was obtained from patients who met inclusion criteria before ultrasonic evaluation of the chest. The ultrasonic examinations were performed before radiographic evaluation when possible or while the chest x-ray film was being developed, allowing the ultrasonographer to remain blinded during the examination; patients with a confirmed diagnosis of pneumothorax before ultrasound were excluded from analysis.

Ultrasonic evaluation of the chest was performed with a Toshiba ultrasound machine (Model SSH 140A, Toshiba American Medical Systems, Armonk, NY). A 4.0-MHz linear probe was used longitudinally over the anterior chest bilaterally in the third or fourth intercostal space at a focal zone of the pleural interface zone for three to five breath cycles. The intercostal plane was located by identifying the acoustic shadow of the rib in real time while the probe is displaced longitudinally. This discontinuous relief represents a constant landmark that facilitates visualization of the pleura as a hyperechoic line between and below the ribs. The examination was performed initially in the unaffected lung to determine a baseline and to affirm the normal ultrasound findings in patients without pneumothorax. The lung pleura was visualized between rib echogenic windows and observed for evidence of the to-and-fro "sliding" sign on respiration or the "comet tail" artifact. The scan was then repeated in the contralateral chest. Patient demographics including mechanism of injury, the duration of the examination, and findings were recorded on a data sheet for later evaluation.

Patient demographic data including age, mechanism of injury, ultrasound examination results, and chest radiographic findings were collated to determine the sensitivity and spec-

**Table 1** Injury demographics of patient population undergoing ultrasound for pneumothorax

Mechanism	Patients	X-Ray PTX	US PTX	False (+)	False (-)
Blunt	281	11	10/11	0	1/11
Gunshot	22	6	6/6	0	0
Stab	61	9	9/9	0	0
Spontaneous	18	13	12/13	0	1/13
Total	382	39/39	37 /39	0/39	2 /39

PTX, pneumothorax; US, ultrasound.

ificity of pulmonary ultrasound in the diagnosis of pneumothorax. Statistics were performed with  $\chi^2$  analysis with  $\kappa$  correction.

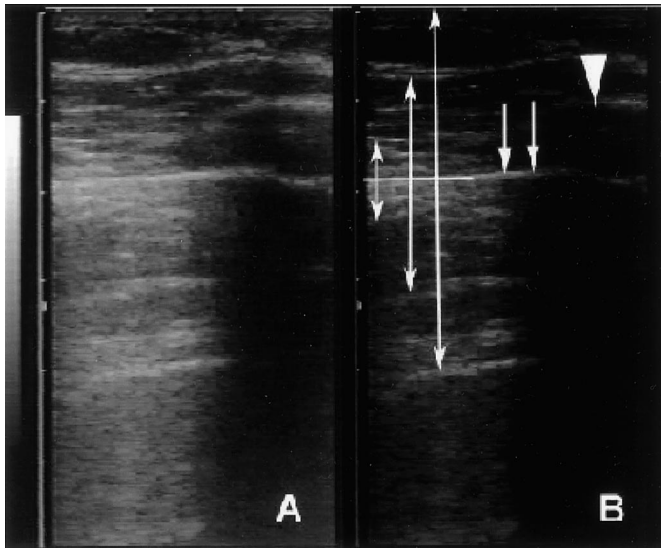
## RESULTS

Patients were actively enrolled in the study over the period July 1, 1999, to March 1, 2000. Although it is impossible to determine how many patients were potentially enrollable during the study period, the most common reasons for nonenrollment were patient instability, inability to obtain consent, and previously confirmed diagnosis of pneumothorax or hemothorax.

There were 382 patients who fulfilled inclusion criteria during the enrollment period and had ultrasound of the thorax performed. The majority were male patients (74%), and the injury demographics of the patient population reflect an urban Level I trauma center (Table 1). The average time required to complete the ultrasound examination was 2 to 3 minutes en toto.

Pleural lung sliding was readily visualized in all of the patients without a pneumothorax (343 of 382), for a true-negative rate of 100% (Fig. 1). There were no comet tail artifacts noted in this patient subgroup. The ultrasonic examination was suboptimal in one patient with a spontaneous pneumothorax and one patient with blunt chest trauma and rib fractures. Both of these patients had moderate subcutaneous emphysema, which made the examination considerably more difficult. If these patients are included in the analysis, the sensitivity or true-positive rate is 95% ( $p < 0.0001$  by  $\chi^2$  analysis with  $\kappa$  correction). One patient had an initial negative chest radiograph and a positive ultrasound examination after a stab wound to the chest; a repeat chest radiograph 4 hours later demonstrated an apical pneumothorax. Although this patient may not have had a pneumothorax on initial ultrasound evaluation, an alternative explanation is that the ultrasound correctly identified a small pneumothorax below the detection threshold of portable radiography. Therefore, this patient was not scored as a false-positive examination.

Rib fractures were occasionally demonstrated in some of the patients during the thoracic ultrasound examination. Modest pressure on the transducer overlying the contused or fractured rib was well tolerated by the patients; a presumptive diagnosis of rib fracture was inferred when cortical discontinuity or a constant transverse echogenic line was noted in the rib.



**Fig. 1.** The appearance of a still image of a pneumothorax on thoracic ultrasound does not differ significantly from a normal chest. (A) A routine quality scan of the anterior thorax. (B) Ultrasound highlighting an anterior rib border (large pointer), the visceral and parietal interface (straight line and double arrows), and interval acoustic reverberation artifacts that may be present in patients with pneumothorax (variable length arrows). The exclusion of pneumothorax is made by demonstrating dynamic to-and-fro sliding at the visceral and parietal pleural interfaces.

The detection of hemothorax was not directly assessed by this study, and is part of the routine focused abdominal ultrasound examination. Nonetheless, 12 patients were noted to have concomitant hemothorax that was visualized on the abdominal examination on either upper quadrant portal using a 3.74-MHz curvilinear abdominal probe. The hemothorax was confirmed in all patients during the thoracic examination by additional scanning in the lower thoracic area (eighth to tenth intercostal space in the lateral clavicular line).

## DISCUSSION

Pneumothorax frequently accompanies penetrating chest trauma and significant blunt chest injury, and occurs after barotrauma. The diagnosis of pneumothorax is generally made with a combination of symptoms and physical examination findings, and is confirmed with chest radiography or, occasionally, computed tomographic scan. Although a moderate pneumothorax is generally not life threatening, delays in diagnosis and therapy may result in progression of respiratory compromise.

The absence of immediate radiographic capabilities because of patient instability, remote location, or other factors complicates the diagnosis of pneumothorax and may necessitate directed action in patients with a high suspicion of pneumothorax alone. Although the potential morbidity of a nontherapeutic chest tube is considerably less than that of a missed critical pneumothorax or hemothorax, placement of a

chest tube complicates patient management, especially in situations where care is provided in remote areas. This concern is particularly evident in military conflicts and aerospace medicine.

Construction of the International Space Station is ongoing, with occupancy planned in the next year. The Crew Health Care System aboard the International Space Station will be equipped to provide immediate emergency care for the purpose of patient stabilization and emergency egress using an escape vehicle.<sup>5</sup> There is no planned radiologic capability aboard the International Space Station because of power and weight constraints. The Health Research Facility is a payload manifested for the International Space Station Laboratory Module that will have ultrasound capability for research and, possibly, operational use by the Crew Medical Officer. The risk of pneumothorax secondary to the hypobaric exposure during space walks, and the inherent risks of blunt chest injury caused by kinetic impacts from large structures and payloads, predicate that diagnostic imaging of the chest may be a requirement on-orbit. The clinical presentation of this illness or injury in the environmental control system with high ambient noise levels may prevent proper diagnosis of pneumothorax by auscultation.

Although ultrasound has proven diagnostic accuracy in abdominal applications, it has not been widely used in the chest. Direct ultrasonographic evaluation of the lung is hampered by the high acoustic impedance of air-containing structures.<sup>6</sup> Nonetheless, pneumothorax may be excluded on the basis of the somewhat paradoxical visualization of artifacts resulting from the lung–chest wall interface.<sup>7</sup> In a normal patient, a lung–chest wall interface or pleural line is seen that is accompanied by a to-and-fro sliding motion, “lung sliding” or “gliding,” synchronized with respiration.<sup>8</sup> A secondary finding, the comet tail artifact, is produced by highly reflective objects in the scanning field, such as water-rich structures in the lung, and manifests as an echogenic band that extends from the object deep into the field.<sup>9</sup> The comet tail artifact is produced by the visceral pleura; therefore, the presence of this sign excludes pneumothorax. Although the comet tail artifact has been described in many patient populations, it is generally produced by small air collections or consolidation of the lung; therefore, the prevalence and utility of this finding in trauma patients is questionable. Furthermore, subcutaneous shotgun pellets or subcutaneous emphysema may cause the comet tail sign; therefore, caution must be exercised when interpreting this finding in trauma patients.

The first reported use of ultrasound to diagnose pneumothorax was in a veterinary journal, where pneumothorax in a horse was diagnosed, allowing percutaneous aspiration.<sup>10</sup> Subsequently, over 100 cases of pneumothorax have been diagnosed by thoracic ultrasound, predominantly in isolated series.<sup>11–13</sup> The technique has been examined in ventilated patients and after lung biopsy in Europe; however, it has not been widely evaluated in the United States.



The sensitivity of lung ultrasound in the detection of pneumothorax appears comparable to or perhaps greater than routine radiography. Prior investigators have attempted to correlate ultrasound findings with the size of the pneumothorax and found minimal correlation.<sup>6</sup> Unfortunately, this study used archived tapes of the examination, which did not allow the operator to compare the two hemithoraces or to investigate subtle findings in the chest, suggesting that a trained operator in attendance is essential. Nonetheless, sensitivities greater than 90% have been reported in patients with pneumothorax.<sup>7-9,13</sup> Unconfirmed data analysis from this trial and animal work suggest that modest pneumothorax can be diagnosed with visualization of segmental lung sliding or localized areas of pleural nonvisualization.

Thoracic ultrasound has been used sporadically in trauma patients with apparent accuracy; however, validation of the technique has not been accomplished to date. This prospective, blinded evaluation demonstrates that pneumothorax can be reliably diagnosed by thoracic ultrasound in trauma patients by nonvisualization of lung sliding. There were no false-positive examinations in this study, and the sensitivity was 94%. Although not specifically addressed in this study, rib fractures and hemothorax were also noted in a number of patients; ultrasound may provide diagnostic confirmation of these conditions.

The technique is quickly learned by operators familiar with ultrasound use in abdominal trauma and adds less than 2 to 3 minutes to the total evaluation. Since the diagnosis of pneumothorax relies on the absence of normally present findings, operator recognition of lung sliding is essential, suggesting that scanning of the thoracic cavity should be incorporated into routine abdominal evaluations to increase familiarity.

There are key technical points of thoracic ultrasound that deserve mention. First, there is consensus that high-frequency transducers are required for optimal images and that dynamic images are required to differentiate pneumothorax from normal lung fields. Scanning should begin in the unaffected lung to confirm the presence of lung sliding. Probe placement is facilitated by identification of the echogenic rib in the lateral clavicular line in the third to fourth interspace and directing the probe inferiorly to allow visualization of lung sliding in the midportion of the viewing screen. After confirmation of lung sliding, the contralateral chest is then scanned for the presence or absence of lung sliding for a number of respiratory cycles; cooperative patients are asked to increase their respiratory efforts. Lung sliding may be absent in patients without pneumothorax who have extensive pleural scarring or adult respiratory distress syndrome; the ultrasonic diagnosis of pneumothorax in these patients appears to be considerably more challenging.

Thoracic ultrasound for the detection of pneumothorax is a clinically attractive modality that can be readily learned with minimal instruction. The surface of the lung is easily visualized with a high-frequency probe and can be rapidly

verified in the normal contralateral chest. The scan can be concomitantly accomplished as other therapeutic maneuvers are performed and has a sensitivity comparable to or greater than radiography. The rediscovery of this technique, mandated by requirements of the space program, suggests that trauma ultrasonographic evaluation should be broadened to include the thorax. The verification of thoracic ultrasound, coupled with newer, portable ultrasound equipment, may allow expanded application of ultrasound in clinical situations where radiography is difficult or impossible.

## REFERENCES

1. Waligora JM, Powell MR, Saueer RL. Spacecraft life support systems. In: Nicogossian AE, ed. *Space Physiology and Medicine*. Philadelphia: Lea & Febiger; 1994:109-127.
2. Raymond CA. When medical help is really far away. *JAMA*. 1988; 259:2343-2344.
3. McCuaig KE, Houtchens BA. Management of trauma and emergency surgery in space. *J Trauma*. 1992;33:610-625.
4. Dulchavsky SA, Hamilton DR, Diebel LN, Sargsyan AE, Billica RD, Williams DR. Thoracic ultrasound diagnosis of pneumothorax. *J Trauma*. 1999;47:970-971.
5. Space Station Projects Office. *Requirements of an In-Flight Medical Crew Health Care System for Space Station*. Houston, TX: NASA Johnson Space Center; 1992. NASA JSC Document 31013 Rev D.
6. Siston CL, Reiheld CT, Spencer BG, Wallace KK. Detection and estimation of the volume of pneumothorax using real-time ultrasonography. *AJR Am J Roentgenol*. 1996;166:317-321.
7. Lichtenstein DA, Menu Y. A bedside ultrasound sign ruling out pneumothorax in the critically ill. *Chest*. 1995;108:1345-1348.
8. Wernerck K, Lalanski M, Peters PE, Hansen J. Pneumothorax: evaluation by ultrasound—preliminary results. *J Thorac Imaging*. 1987;7:76-78.
9. Lichtenstein DA, Meziere G, Biderman P, Gepner A. The comet tail artifact: an ultrasound sign ruling out pneumothorax. *Intensive Care Med*. 1999;25:383-388.
10. Ratanen NW. Diagnostic ultrasound: diseases of the thorax. *Vet Clin North Am*. 1986;2:49-66.
11. Targhetta R, Bourgeois JM, Balmes P. Echography of pneumothorax. *Rev Mal Respir*. 1990;7:575-579.
12. Targhetta R, Bougeois JM, Chavagneux R, Balmes P. Diagnosis of pneumothorax by ultrasound immediately after ultrasound immediately after ultrasonically guided aspiration biopsy. *Chest*. 1992;101:855-856.
13. Goodman TR, Traill ZC, Phillips AJ, Berger J, Gleeson FV. Ultrasound detection of pneumothorax. *Clin Radiol*. 1999;54:736-739.

## DISCUSSION

**Dr. Grace S. Rozycki** (Atlanta, Georgia): Prompt detection and treatment are critical factors in saving lives of patients with major thoracic injury, but the unreliability of physical examination alone in assessing the patient may delay appropriate management. As an extension of the physical examination, ultrasound in the hands of surgeons is an integral part of the patient's assessment and those of us who use it routinely find it hard to imagine life without it.

In this study, the authors used ultrasound to evaluate 382 injured patients for the presence or absence of a pneumothorax. The occurrence of the characteristic pleural lung sliding

was observed in those patients without a pneumothorax. They compared their results with that of the chest radiograph and found that ultrasound had a sensitivity of 95.5% for the detection of pneumothorax and, it was much more rapid, as performance times averaged only 2 to 3 minutes.

This study is not only an accomplishment for the investigators but for all surgeons as we continue to forge ahead with the use of ultrasound as a key diagnostic tool for the evaluation of patients. The authors illustrate how real-time imaging is successfully used to obtain instantaneous results, expedite the resuscitation, and initiate earlier treatment of a patient with thoracic injury. Additionally, the authors emphasize important artifacts and physics principles that are a fundamental part of image interpretation and a necessary component of the ultrasound diagnosis of a pneumothorax. I have several questions and one comment for the authors:

1. A key part of the ultrasound examination for the detection of a pneumothorax is the recognition of two findings: (1) "lung sliding", that is, the displacement of the visceral pleura from the parietal pleura, and (2) the comet-tail artifact, which is based in the acoustic impedance mismatch of lung, pleura, and air. How would you suggest that the ultrasound technique be altered so that it can be used to assess patients with lung disease such as those in the intensive care unit? How would you recommend that these physics principles be taught to those who are just learning the essentials of ultrasound? Can you postulate a learning curve for this examination, such as that reported by Shackford and colleagues for the FAST examination?

2. The authors describe the ultrasound technique used for the detection of a pneumothorax but, do not describe the patients' physical examination findings. Although ultrasound is an extension of the physical examination, it does not replace it. How many pneumothoraces could have been diagnosed clinically, especially those that occurred in patients with penetrating injuries?

The examination was performed using a 4.0 MHz linear transducer which is different than the 3.5 MHz convex transducer commonly used to perform the FAST examination and FAST plus two that is, the thoracic evaluation for traumatic hemothorax. Although the frequencies are similar, the arrays are different. In my experience, a 7.5 MHz transducer allows better visualization of the lung-pleural interface and has broader applicability because it can be used to evaluate patients for other acute problems, such as a soft tissue abscess. Therefore, the purchase of a 7.5 MHz linear transducer would seem more cost-effective.

The use of surgeon-performed ultrasound continues to expand, especially as used to evaluate patients with acute surgical problems. Overall, the authors are to be congratulated on bringing to light yet another use of surgeon-performed ultrasound for the evaluation of the injured patient.

I would like to express my appreciation to the program committee for the privilege of discussing this paper.

**Dr. R. Stephen Smith** (Wichita, Kansas): I just have a brief comment. You introduced this concept to me about 3 months ago, and I was very skeptical initially, but after seeing your real-time images and viewing some of the videotapes, we have actually started using this in our institution, initially just for experimentation and to see if we could do it. The residents have picked this technique up so quickly that we have now incorporated this into our standard FAST examination. I want to congratulate you on an excellent study.

**Dr. Michael Moncure** (Kansas City, Kansas): I would like to applaud the author and ask whether the technique is fairly good in diagnosing resolution of the pneumothorax after chest tube placement?

**Dr. Scott A. Dulchavsky** (closing): Thank you, Dr. Rozycki, and we acknowledge your widespread contributions in the field of surgeon-associated ultrasound.

First, you asked about alterations in technique in the ICU patient. Portability is key in those individuals. I would suggest some of the newer machines that are more lightweight with high fidelity are perfect for this application. In the ICU patient, often with pulmonary involvement, we would rely more on the comet tail sign, which is more widespread in patients in the ICU, especially with infiltration.

The physics principles should be taught. I believe the ACS model for how we teach ultrasound with many of the AAST members serving as instructors would be a paradigm for that with a small module on thoracic ultrasonography, showing both the normal and abnormal.

Fortunately, as mentioned, the learning curve is very steep, and it is considerably easier to learn this than the standard FAST examination, and my residents have relayed that after three to five examinations, they are relatively comfortable with this.

This technique is an adjunct. It absolutely does not replace physical examination and, although we did not use physical examination as the gold standard, I anticipate our physical examination accuracy to be on the level of 20%, which is between the 10% and 40% that is reported in the literature.

Finally, you astutely pointed out that a 4-MHz probe is suboptimal. I would completely agree with that. We advise use of the more higher fidelity probes—we are currently using a 10-MHz probe that provides excellent visualization.

There is unfortunately no one probe that you can use for both the abdominal and thoracic examinations to date.

Thank you, Dr. Smith. If I have peaked your interest, I have done a good job. Now we believe the thoracic ultrasound examination findings over the chest radiograph when it is negative, and we will forge on with a CAT scan.

To answer Dr. Moncure's question, absolutely. That is a wonderful point and you have a very nice control in that you see the presence of lung sliding reestablished once you put the chest tube on suction.

Thank you again for the privilege of the floor.